

Drug-resistant disseminated polyclonal *Mycobacterium avium* complex in a patient with AIDS: a case report and review of the literature

P. Bagella¹, G. Madeddu¹, R. Are¹, F. Peruzzu¹, G. Bagella²,
G.M. Calia¹, M.S. Mura¹

¹Unit of Infectious Diseases, Department of Clinical and Experimental Medicine, University of Sassari, Sassari, Italy

²Unit of Radiology, Sassari University Hospital, Sassari, Italy

ABSTRACT:

— *Mycobacterium avium* complex (MAC) disseminated infection is an opportunistic infection that occurs almost exclusively in immunocompromised individuals. We report an interesting case of multidrug-resistant polyclonal disseminated MAC infection in a patient with AIDS. During combination anti-MAC therapy, cultures became negative but he developed sensorineural hearing loss as a result of azithromycin ototoxicity.

— **Key words:** *Mycobacterium avium* complex, AIDS, Polyclonal, Drug-resistant, Azithromycin, Ototoxicity.

INTRODUCTION

The development of Highly Active Antiretroviral Therapy (HAART) has resulted in marked changes in the outcome of Human Immunodeficiency Virus (HIV) disease, with significant reductions in mortality as well as opportunistic infections¹⁻³. In this scenario, the risk of non-HIV-related morbidity, including cardiovascular and bone disease, neurocognitive impairment and malignancies, has dramatically increased in recent years⁴⁻²⁰.

However, morbidity and mortality in Acquired Immunodeficiency Virus Syndrome (AIDS) presenters are still related to opportunistic infections, including *Mycobacterium avium* complex (MAC)²¹. MAC organisms are non-chromogenic slow-growing mycobacteria classified in Runyon group III. The complex consists of three species, *M. avium*, *M. intracellulare*, and *M. lepraemurium*. *Mycobacterium avium* consists of three subspecies, of which only *M. avium* subspecies *avium* is a human pathogen.

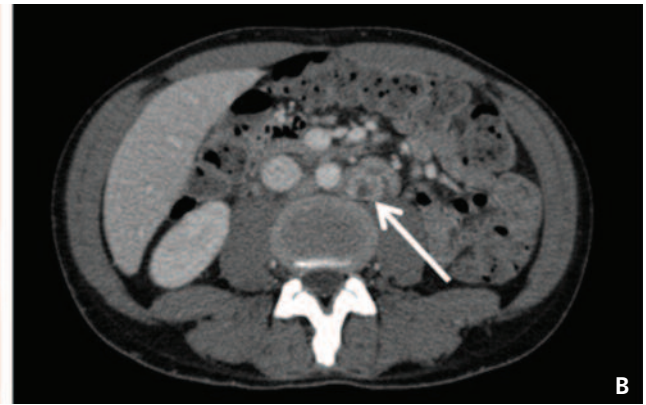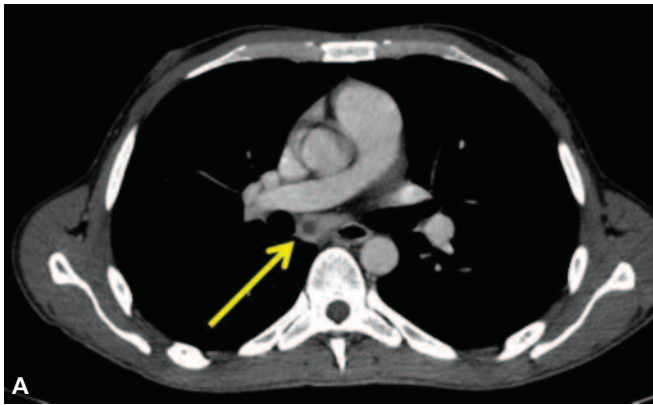
Here, we report a case of multidrug-resistant polyclonal disseminated MAC (DMAC) infection in a patient with AIDS.

CASE REPORT

Our patient, a 37-year-old HIV-positive man, was diagnosed as a late presenter and admitted to our Infectious Diseases Clinic with wasting syndrome and *Cytomegalovirus* (CMV) disease. At baseline, plasma HIV RNA was 6200000 copies/ml and the CD4+ T-cell count was 3 cells/ μ l (3%). Therefore, he immediately started antiretroviral therapy, antiviral therapy for CMV along with supportive and opportunistic infection prophylactic therapy for *Pneumocystis pneumonia* and *Toxoplasmosis*.

According to international guidelines, he also started chemoprophylaxis for MAC infection with azithromycin 1200 mg once weekly. However, prophylaxis was interrupted because of a progressive elevation of serum alkaline phosphatase and gamma-glutamyl transferase.

A few months later, he was admitted again to our Clinic due to fever, weight loss and progressive elevation of liver enzymes. A Computed Tomography scan showed multiple enlarged mediastinal and abdominal lymph nodes (Figure 1). He was diagnosed with DMAC infection by direct smear, polymerase chain reaction (PCR) and cultures of sputum and stool specimens.



He started empiric treatment with azithromycin 600 mg once daily, rifabutin 150 mg daily and ethambutol 15 mg/kg daily with poor improvement, persistent elevation of hepatic enzymes, fever, malaise and pancytopenia. A bone marrow biopsy and bone marrow blood cultures were positive for MAC. Microbiological analysis of MAC strain cultures (on both sputum and stool) showed resistance to several first-line antimicrobials, including ethambutol and rifabutin (Table 1). On the basis of the antimicrobial susceptibility testing, moxifloxacin was added to the other drugs. The treatment was continued with ethambutol, even if resistant, until the end of the second month, because of its important role in preventing macrolides resistance²². Treatment with rifabutin was also continued due to the sensibility of the antimicrobial susceptibility testing from bone marrow. After twenty days of antimicrobial therapy, culture became negative and the patient experience a good clinical and laboratory response. However, he started complaining of a progressive hearing loss and the audiogram revealed mild to moderate bilateral sensorineural hearing loss. Suspecting azithromycin ototoxicity, antimicrobial treatment was modified with intermittent azithromycin administration (600 mg three times weekly)^{23,24}.

At this time, after two months since the beginning of the new regimen, cultures from sputum, blood and stool, as well as cultures from bone marrow, are still negative and the patient reports a sensible improvement in hearing impairment.

DISCUSSION

MAC is a group of common environmental bacteria of relatively low virulence in immunocompetent individuals. MAC organisms have been isolated from a variety of environmental sources, including water, soil, birds, pigs, and cattle. The exact route of acquisition from environmental sources to humans is uncertain, but indirect evidence favours acquisition through either the gastrointestinal or the respiratory tracts²³.

However, the mechanisms of subsequent dissemination are uncertain. The sites where MAC are most frequently found include the blood, bone marrow, lymph nodes, gastrointestinal tract, liver, and spleen²³.

A critical requirement for the development of DMAC infection is severe CD4+ lymphocyte depletion (<50 cells/ μ l). DMAC disease is a life threatening illness that oc-

curs almost exclusively in advanced HIV disease and rarely among other severely immunocompromised individuals²³.

Clinical features of disseminated MAC infection are not specific and include fever (>80%), night sweats (>35%), weight loss (>25%), abdominal pain or diarrhoea²⁵. Laboratory results may show anaemia, elevated serum alkaline phosphatase, and elevated serum lactate dehydrogenase. Hence, the diagnosis of DMAC infection can only be made by using laboratory tests. The preferred investigation for DMAC infection is based on mycobacterial blood, sputum and stool cultures. All cultures for mycobacteria should include both solid and broth (liquid) media for the detection and enhancement of growth²⁶. Occasionally, the diagnosis is made by bone marrow, lymph node or duodenal biopsy²⁷. Because of differences in antimicrobial susceptibility that determine treatment options, species-level identification of non-tuberculous mycobacterial diseases is becoming increasingly important²⁸. We utilized Acridium ester-labeled DNA probes specific for MAC.

Successful treatment is based on both anti-mycobacterial therapy and HIV treatment to improve the under-

Table 1. Minimum inhibitory concentration for the two *Mycobacterium avium* strains isolated from sputum and bone marrow.

| DATE SOURCE | 18/10/2014 SPUTUM | | | 24/11/2014 BONE MARROW | | |
|----------------|----------------------|------|------|---------------------------|------|-----|
| | EMB | 16 | ug/m | R | - | |
| RIF | 2 | ug/m | R | - | | S |
| RBN | 0.5 | ug/m | S | 0.5 | ug/m | S |
| PIR | >16 | ug/m | R | >16 | ug/m | R |
| CLR | 2 | ug/m | S | 2 | ug/m | S |
| STR | 4 | ug/m | R | - | | N/D |
| ISN | >1 | ug/m | R | - | | R |
| CIP | 2 | ug/m | S | 1 | ug/m | S |
| LEV | 4 | ug/m | S | 2 | ug/m | S |
| LIN | >16 | ug/m | R | 4 | ug/m | S |
| MOX | 1 | ug/m | S | 1 | ug/m | S |
| DOX | >16 | ug/m | R | - | | - |
| IMI | >16 | ug/m | R | >16 | ug/m | R |
| ETI | >16 | ug/m | R | >16 | ug/m | R |
| AMK | 0.5 | ug/m | S | 0.5 | ug/m | S |
| A/AC | >16 | ug/m | R | >16 | ug/m | R |

AMK: amikacin; A/AC: Amoxicillin clavulanate; CIP: ciprofloxacin; CLR: clarithromycin; DOX: doxycycline; EMB: ethambutol; ETI: ethionamide; IMI: imipenem; ISN: isoniazid; LEV: levofloxacin; MOX: moxifloxacin; N/D: not determined; PIR: pyrazinamide; R: resistant; RBN: rifabutin; RIF: rifampin; S: sensitive; STR: streptomycin

lying immunosuppression. The cornerstone of therapy for DMAC is a macrolide, usually in addition to rifabutin, easier to use with most antiretroviral drugs than rifampicin, and ethambutol.

For patients with macrolide-resistant strains, treatment regimens are less successful. Possible options include aminoglycosides, such as amikacin, quinolones, such as moxifloxacin, and linezolid.

Treatment of MAC in patients with AIDS should be considered lifelong, unless immune restoration is achieved by antiretroviral therapy. MAC treatment may be stopped, with a low risk of recurrence, for patients who are asymptomatic and have achieved a CD4+ T-cell count greater than 100 cells/ μ l for at least 12 months. Secondary prophylaxis should be reintroduced if the CD4+ T-cell count decreases to less than 100 cells/ μ l²⁸.

Azithromycin has a very long half-life, up to 70 hours, and it is concentrated in phagocytes and tissues, including the lung. Intermittent azithromycin, 1200 mg on a once-weekly basis, has been shown to be effective as chemoprophylaxis against DMAC. Only few data are available in literature about the use of intermittent therapy for DMAC. Some prospective trials demonstrated that multidrug regimens including azithromycin, given intermittently, can be effective to obtain negative cultures and are generally well tolerated²³.

Azithromycin can rarely cause ototoxicity. From the few data available in the literature on azithromycin-related ototoxicity in HIV-infected patients, symptoms usually developed within 30-90 days and resolved 2-11 weeks after the drug discontinuation. Hearing loss usually is bilateral and mild to moderate. Azithromycin toxicity appears dose and serum level related. The mechanism of dose-related ototoxicity is unclear: patients who received standard azithromycin dosages for respiratory infection had considerably less drug exposure than those who received it for HIV-associated indications. HIV-positive patients may also be at risk of developing hearing complications secondary to opportunistic infections or other potentially ototoxic drugs²⁹.

Finally, it has been reported that almost 24% of patients with AIDS and DMAC infection have a polyclonal infection. Of importance, the different strains of MAC that simultaneously infected the patient may have different antimicrobial susceptibility patterns³⁰.

In conclusion, the emergence of multidrug-resistant MAC represents a threat to HIV/AIDS patients. The existence of polyclonal infection among AIDS patients with disseminated MAC is an additional factor to be considered. Our case suggests that multidrug regimens including azithromycin, given intermittently, can be effective to achieve negative culture in patients with resistant MAC disease. However, patients receiving prolonged high-dose azithromycin therapy should be monitored for the development of ototoxicity.

References

1. Palella FJ Jr, Delaney KM, Moorman AC, Loveless MO, Fuhrer J, Satten GA, Aschman DJ, Holmberg SD. Declining morbidity and mortality among patients with advanced human immunodeficiency virus infection. HIV Outpatient Study Investigators. *N Engl J Med* 1998; 338: 853-860.
2. Mocroft A, Ledergerber B, Katlama C, Kirk O, Reiss P, d'Arminio Monforte A, Knysz B, Dietrich M, Phillips AN, Lundgren JD; EuroSIDA study group. Decline in the AIDS and death rates in the EuroSIDA study: an observational study. *Lancet* 2003; 362: 22-29.
3. Lohse N, Hansen AB, Pedersen G, Kronborg G, Gerstoft J, Sørensen HT, Vaeth M, Obel N. Survival of persons with and without HIV infection in Denmark, 1995-2005. *Ann Intern Med* 2007; 146: 87-95.
4. Madeddu G, Spanu A, Solinas P, Calia G M, Lovigu C, Mannazzu M, Falchi A, Mura MS, Madeddu G. Bone mineral loss and vitamin D metabolism impairment in HIV infected patients receiving highly active antiretroviral therapy (HAART). *Q J Nucl Med Mol Imaging* 2004; 48: 39-48.
5. Madeddu G, Spanu A, Chessa F, Calia GM, Lovigu C, Solinas P, Mannazzu M, Falchi A, Mura MS, Madeddu G. Thyroid function in human immunodeficiency virus patients treated with highly active antiretroviral therapy (HAART): a longitudinal study. *Clin Endocrinol* 2006; 64: 375-383.
6. Bonfanti P, Ricci E, de Socio G, Zeme D, Carradori S, Penco G, Parruti G, Grosso C, Madeddu G, Vichi F, Bini T, Martinelli C, Melzi S, Quirino T; CISAI Study Group. Metabolic syndrome: a real threat for HIV-positive patients?: Results from the SIMONE study. *J Acquir Immune Defic Syndr* 2006; 42: 128-131.
7. Bonfanti P, De Socio GL, Marconi P, Franzetti M, Martinelli C, Vichi F, Penco G, Madeddu G, Orofino G, Valsecchi L, Vitiello P, Menzaghi B, Magni C, Ricci E. Is metabolic syndrome associated to HIV infection per se? Results from the HERMES study. *Curr HIV Res* 2010; 8: 165-171.
8. De Socio GV, Ricci E, Parruti G, Maggi P, Madeddu G, Quirino T, Bonfanti P. Chronological and biological age in HIV infection. *J Infect* 2010; 61: 428-430.
9. Bonfanti P, De Socio GV, Ricci E, Antinori A, Martinelli C, Vichi F, Penco G, Madeddu G, Orofino G, Valsecchi L, Rusconi S, Menzaghi B, Pocaterra D, Quirino T. The feature of Metabolic Syndrome in HIV naive patients is not the same of those treated: results from a prospective study. *Biomed Pharmacother* 2012; 66: 348-353.
10. Madeddu G, Fois AG, Calia GM, Babudieri S, Soddu V, Becchiu F, Fiori ML, Spada V, Lovigu C, Mannazzu M, Caddeo A, Piras B, Pirina P, Mura MS. Chronic obstructive pulmonary disease: an emerging comorbidity in HIV-infected patients in the HAART era? *Infection* 2013; 41: 347-353.
11. Schillaci G, Maggi P, Madeddu G, Pucci G, Mazzotta E, Penco G, Orofino G, Menzaghi B, Rusconi S, Careni L, Celesia BM, Martinelli C, Bonfanti P, De Socio GV; CISAI Study Group. Symmetric ambulatory arterial stiffness index and 24-h pulse pressure in HIV infection: results of a nationwide cross-sectional study. *J Hypertens* 2013; 31: 560-567.
12. Zanet E, Berretta M, Martellotta F, Cacopardo B, Fisichella R, Tavio M, Berretta S, Tirelli U. Analcancer: focus on HIV-positive patients in the HAART-era. *Curr HIV Res* 2011; 9:70-81.
13. Pinzone MR, Fiorica F, Di Rosa M, Malaguarnera G, Malaguarnera L, Cacopardo B, Zanghi G, Nunnari G. Non-AIDS-defining cancers among HIV-infected people. *Eur Rev Med Pharmacol Sci* 2012; 16: 1377-1388.
14. Berretta M, Zanet E, Basile F, Ridolfo AL, Di Benedetto F, Bearz A, Berretta S, Nasti G, Tirelli U. HIV-positive patients with liver metastases from colorectal cancer deserve the same therapeutic approach as the general population. *Onkologie* 2010; 33: 203-204.
15. Scarpino M, Pinzone MR, Di Rosa M, Madeddu G, Focà E, Martellotta F, Schioppa O, Ceccarelli G, Celesia BM, d'Etorre G, Vullo V, Berretta S, Cacopardo B, Nunnari G. Kidney disease in HIV-infected patients. *Eur Rev Med Pharmacol Sci* 2013; 17: 2660-2667.
16. Castronuovo D, Cacopardo B, Pinzone MR, Di Rosa M, Martellotta F, Schioppa O, Moreno S, Nunnari G. Bone disease in the setting of HIV infection: update and review of the literature. *Eur Rev Med Pharmacol Sci* 2013; 17: 2413-2419.

17. Nunnari G, Berretta M, Pinzone MR, Di Rosa M, Berretta S, Cunsolo G, Malaguarnera M, Cosentino S, De Paoli P, Schnell JM, Cacopardo B. Hepatocellular carcinoma in HIV positive patients. *Eur Rev Med Pharmacol Sci* 2012; 16: 1257-1270.
18. Zanet E, Berretta M, Benedetto FD, Talamini R, Ballarin R, Nunnari G, Berretta S, Ridolfo A, Lleshi A, Zanghì A, Cappellani A, Tirelli U. Pancreatic cancer in HIV-positive patients: a clinical case-control study. *Pancreas* 2012; 41: 1331-1335.
19. Pinzone MR, Di Rosa M, Cacopardo B, Nunnari G. HIV RNA suppression and immune restoration: can we do better? *Clin Dev Immunol* 2012; 2012: 515962.
20. Pinzone MR, Di Rosa M, Malaguarnera M, Madeddu G, Focà E, Ceccarelli G, d'Ettore G, Vullo V, Fisichella R, Cacopardo B, Nunnari G. Vitamin D deficiency in HIV infection: an underestimated and undertreated epidemic. *Eur Rev Med Pharmacol Sci* 2013; 17: 1218-1232.
21. Celesia BM, Castronuovo D, Pinzone MR, Bellissimo F, Mughini MT, Lupo G, Scarpino MR, Gussio M, Palermo F, Cosentino S, Cacopardo B, Nunnari G. Late presentation of HIV infection: predictors of delayed diagnosis and survival in Eastern Sicily. *Eur Rev Med Pharmacol Sci* 2013; 17: 2218-2224.
22. Griffith DE, Brown-Elliott BA, Langsjoen B, Zhang Y, Pan X, Girard W, Nelson K, Caccitolo J, Alvarez J, Shepherd S, Wilson R, Graviss EA, Wallace RJ Jr. Clinical and molecular analysis of macrolide resistance in *Mycobacterium avium* complex lung disease. *Am J Respir Crit Care Med* 2006; 174: 928-934.
23. Griffith DE, Brown BA, Murphy DT, Girard WM, Couch L, Wallace RJ Jr. Initial (6-month) results of three-times-weekly azithromycin in treatment regimens for *Mycobacterium avium* complex lung disease in human immunodeficiency virus-negative patients. *J Infect Dis* 1998; 178: 121-126.
24. Griffith DE, Winthrop KL. *Mycobacterium Avium* Complex lung disease therapy. *Am J Respir Crit Care Med* 2012; 186: 477-479.
25. Nightingale SD, Byrd LT, Southern PM, Jockusch JD, Cal SX, Wynne BA. Incidence of *Mycobacterium avium*-intracellular complex bacteremia in human immunodeficiency virus-positive patients. *J Infect Dis* 1992; 165: 1082-1085.
26. National Committee for Clinical Laboratory Standards. Susceptibility testing of mycobacteria, nocardiae, and other aerobic actinomycetes. Approved Standard. Wayne, PA: NCCLS; 2003. Document No. M24-A.
27. Shafran SD. Prevention and treatment of disseminated *Mycobacterium avium* complex infection in Human HIV infected individuals. *Int J Infect Dis* 1998; 3: 39-47.
28. Griffith DE, Aksamit T, Brown-Elliott BA, Catanzaro A, Daley C, Gordin F, Holland SM, Horsburgh R, Huit G, Iademarco MF, Iademarco MF, Iseman M, Olivier K, Ruoss S, von Reyn CF, Wallace RJ Jr, Winthrop K, ATS Mycobacterial Diseases Subcommittee. American Thoracic Society; Infectious Diseases Society of America. An official ATS/IDSA statement: diagnosis, treatment, and prevention of nontuberculous mycobacterial diseases. *Am J Respir Crit Care Med* 2007; 175: 367-416.
29. Tseng AL, Dolovich L, Salit IE. Azithromycin-related ototoxicity in patients infected with human immunodeficiency virus. *Clin Infect Dis* 1997; 24: 76-77.
30. vonReyn CF, Jacobs NJ, Arbeit RD, Maslow JN, Niemczyk S. Polyclonal *Mycobacterium avium* infections in patients with AIDS: variations in antimicrobial susceptibilities of different strains of *M. avium* isolated from the same patient. *J Clin Microbiol* 1995; 33: 1008-1010.