

# Herpetic meningoencephalitis following inactivated COVID-19 vaccine: a coexistence or coincidence?

H. Chaabouni, F. Smaoui, F. Hammami, K. Rekik, A. Chakroun, C. Marrakchi, M. Koubaa, M.B. Jemaa

Department of Infectious Diseases, Hedi Chaker Hospital, Sfax, Tunisia

## ABSTRACT:

- **Objective:** Herpetic meningoencephalitis is characterized by a severe prognosis. Neurological involvement is secondary to recurrence in adults. We report the first case of meningoencephalitis caused by the herpes simplex virus 1 (HSV-1) which occurred immediately after vaccination against the coronavirus disease 2019 (COVID-19).
- **Case presentation:** A 42-year-old woman with no previous medical history received her first dose of the SARS-CoV-2 vaccine [heterologous rAd26 and rAd5 vector-based SARS-CoV-2 vaccine (Sputnik®)] while asymptomatic. Two weeks later, the patient presented with asthenia and obnubilation requiring hospitalization in the Intensive Care Unit of the Infectious Diseases Department (Hedi Chaker Hospital, Sfax, Tunisia). Magnetic resonance brain imaging showed an abnormal signal from the inner side of the right temporal lobe in T1 iso-signal and T2 hyper-signal. The patient tested positive for HSV-1; thus, the diagnosis of herpetic meningoencephalitis was retained. The patient's general condition and her laboratory test results improved after receiving treatment with acyclovir. The treatment was maintained for 14 days and the patient was discharged from the hospital without any central nervous system impairment.
- **Conclusions:** The recurrence of HSV-1 infection following SARS-CoV-2 vaccine is exceptional. We report the first possible link between SARS-CoV-2 vaccination and the recurrence of herpetic meningoencephalitis.
- **Keywords:** COVID-19, Vaccine, Herpetic meningoencephalitis, Acyclovir.

## INTRODUCTION

Meningoencephalitis (ME) is defined by the presence of an inflammatory process of the brain in association with clinical evidence of neurologic dysfunction<sup>1</sup>. It includes concomitant meningeal inflammation, in addition to the encephalitic component.

ME is characterized by the association of fever, headache, and altered level of consciousness<sup>1</sup>. Other findings in patients with ME include acute cognitive dysfunction, behavioral changes, focal neurologic signs, and seizures.

Viruses are the main infectious cause of meningoencephalitis worldwide<sup>2</sup>. According to the literature, the main virus causing ME is the Herpes Simplex Virus (HSV-1). It is responsible for 20% to 50% of viral ME. About 30% of herpetic meningoencephalitis is due to a primary HSV-1 infection, whereas the remaining cases are attributed to viral reactivation or reinfection<sup>3</sup>.

Between 52% and 84% of the human adult population is latently infected by HSV-1<sup>4</sup>. The interaction between HSV-1 and the immune system allows the virus to remain dormant in the host for a lifetime. However, disruptions in the immune system can activate the virus with the po-



This work is licensed under a [Creative Commons Attribution-NonCommercial-ShareAlike 4.0 International License](https://creativecommons.org/licenses/by-nc-sa/4.0/)

tential of meningoencephalitis<sup>5</sup>. Reactivation has been associated with increasing age, HIV infection, physical or emotional stress, fever, exposure to ultraviolet light, tissue damage, and immunosuppression<sup>6,7</sup>. Vaccination seems to be a rare cause of herpetic reactivation.

According to studies<sup>5,8</sup>, herpetic meningoencephalitis was rarely described after the influenza vaccine<sup>8</sup>. It can be hypothesized that this clinical condition develops due to the activation of an autoimmune mechanism after vaccination<sup>5,8</sup>.

Currently, vaccination is a topical issue since it is the most efficient solution to end the severe acute respiratory syndrome coronavirus 2 (SARS-CoV-2) pandemic. Thus, it becomes critical to know whether these vaccines are safe or not. Common side effects are pain at the injection site, fever, fatigue, headache, chills, and diarrhea. The frequency of these side effects varies depending on the vaccine concerned<sup>9</sup>. Cutaneous reactions seem to be frequent after SARS-CoV-2 vaccines and include erythema, swelling, itching, and generalized rashes<sup>10</sup>.

SARS-CoV-2 vaccines can cause neurologic disorders like demyelinating diseases, fever-induced seizures, and other possible side effects<sup>11</sup>.

Here, we report the first case of herpetic meningoencephalitis in a young adult, two weeks after receiving the heterologous rAd26 and rAd5 vector-based SARS-CoV-2 vaccine (Sputnik®).

## CASE PRESENTATION

A 42-year-old woman presented to the Emergency Department (Sfax Center, Tunisia) complaining of fever and confusion. She had no previous medical history.

No previous SARS-CoV-2 infection was reported and no influenza vaccine was received. She received her first dose of the heterologous rAd26 and rAd5 vector-based COVID-19 vaccine (Sputnik®) while she was asymptomatic.

Two weeks after vaccination, the patient suffered from asthenia and obtundation requiring her hospi-

talization in the Intensive Care Unit of the Infectious Diseases Department (Hedi Chaker Hospital, Sfax, Tunisia). On admission, she had a body temperature of 38,5°C, a heart rate of 100 beats/minute, and a Glasgow Coma Score of 10/15. The evolution was marked by the onset of a generalized seizure.

Full blood count (FBC) was normal. Elevated inflammatory markers were noted, with a C-reactive protein level of 100 mg/L (normal level should be less than 6 mg/L). The Transaminase level was normal. Blood cultures were collected on admission. HIV serology was negative.

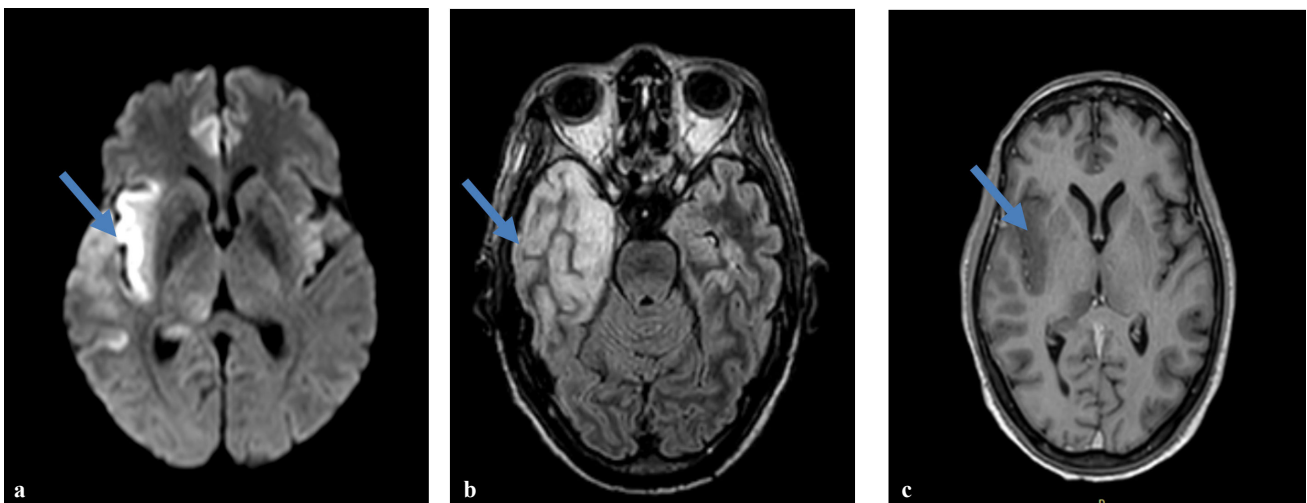
Magnetic resonance brain imaging has shown an abnormal signal from the inner side of the right temporal lobe in T1 iso-signal and T2 hyper-signal (Figure 1).

The cerebrospinal fluid was clear, containing 15 white elements/mm<sup>3</sup>, normoglycorachia with 3.55 mmol/l for a concomitant glycemia at 6 mmol/l, and hyperproteinorachia at 0.51 g/l.

At the Intensive Care Unit, the patient was initially treated with an intravenous third-generation cephalosporin (cefotaxime at a dose of 300 mg/kg/day), corticosteroid (Dexamethasone 10 mg, 4 times per day for 4 days), and acyclovir (at a dose of 10 mg/kg 3 times per day). On the 4<sup>th</sup> day of hospitalization, the positivity of HSV-1 on the cerebrospinal fluid was notified, so the diagnosis was rectified and only treatment with acyclovir was continued. The evolution was marked by the normalization of the neurological exam and the treatment was maintained for 14 days. She was discharged from the hospital without any central nervous system impairment.

## DISCUSSION

The most efficient solution to SARS-CoV-2 pandemic is a safe and efficient vaccine. The vaccine's goal is to produce antibodies that can neutralize pathogens or flag them for destruction by the immune system. An array of modalities including novel techniques are being utilized as the mRNA vaccine platforms, inactivated virus, viral



**Figure 1.** Axial image of cerebral MRI showed (a) high signal intensity on FLAIR imaging within right insular regions. Diffusion-weighted imaging (b) showed restricted diffusion in the right temporal region. Post-contrast T1-weighted images (c) showed no enhancement in the right temporal cortex.

vector, and protein subunit<sup>12</sup>. Regardless of platform used, vaccines could bare the risk of neurological side effects<sup>11</sup>.

Actually, vaccine-related neurological adverse events have previously been reported. For example, demyelinating diseases was linked to Hepatitis B vaccine<sup>13</sup>, Guillain-Barré syndrome (GBS) to the Influenza vaccine<sup>14</sup> and Tetanus vaccines<sup>15</sup>.

Reactivation of herpetic ME has also been described after influenza vaccine administration<sup>16-19</sup>. The pathogenesis of reactivation of HSV could be explained by the temporary loss of immunologic control during influenza A (H1N1) vaccination.

González et al<sup>20</sup> reported a recurrent case of HSV meningoencephalitis reactivation in two consecutive years, occurring a few weeks after his annual vaccine (Vaxigrip®, Sanofi, K7375-2) and (Influvax®, Abbott, HY01N), respectively. Hassman et al<sup>5</sup> presented a patient who suffered from HSV-1 reactivation related episodes (encephalitis, seizure, and retinitis), for three consecutive years within few days after influenza vaccination. The vaccine received each year were respectively Fluvax (2012-2013 formula, GlaxoSmithKline, London, England), Agriflu (2013-2014 formula, Novartis, Basel, Switzerland) and Fluzone (2014-2015 formula, Sanofi Pasteur, Paris, France)<sup>5</sup>.

Regarding SARS-CoV-2 vaccines, some neurological side effects were reported. Referring to Vaccine Adverse Event Reporting System (VAERS) database, there were cases of stroke, Guillain-Barré syndrome (GBS), facial palsy, transverse myelitis, and acute disseminated encephalomyelitis<sup>21</sup>. However, these data were based on passive monitoring, thus biased.

Although rare, mild, and severe neurological side effects have been occasionally reported<sup>21</sup>, their type and frequency depend on the type of vaccine.

For inactivated vaccines, a febrile reaction after vaccines is a common side effect<sup>22</sup> but no febrile seizure was reported so far during the vaccines trials<sup>11</sup>. Concerning autoimmune disorders frequently related to other inactivated vaccines, many reviews<sup>11,23,24</sup> found no relationship between SARS-CoV-2 inactivated vaccines and autoimmune disorders.

Protein subunit vaccine, such as the Novavax vaccine, was considered to be safer because its components contain only recombinant proteins or synthetic peptides without the involvement of infectious viruses<sup>11</sup>. Regarding nucleic acid-based vaccines consisting of DNA or mRNA, the clinical trial published by Polack et al<sup>25</sup> explored the safety of the BNT162b2 mRNA SARS-CoV-2 Vaccine (Pfizer®). Their study<sup>25</sup> including 43,448 participants showed no neurological adverse events in the vaccine group.

Concerning viral vector vaccines, such as in our case, vaccines consist of a recombinant virus (for example Adenovirus) in which genes coding for viral antigens of SARS-CoV-2 have been cloned using recombinant DNA techniques. This vaccine will enter cells and produce the antigen without new viral replication<sup>26</sup>. According to the phase 3 trial published by Voysey et al<sup>27</sup>, there are 3 cases of transverse myelitis reported after the ChAdOx1 nCoV-19 vaccine (AstraZeneca®), but only one was possibly related to vaccination.

The pathogenesis of transverse myelitis remains uncertain. It can be caused by either SARS-CoV-2 antigens or chimpanzee adenovirus antigens inducing immune mechanisms leading to myelitis<sup>28</sup>.

In addition, two patients presented neurological adverse events after vaccination with Janssen Ad26.COVID Vaccine: a case of GBS and a case of facial paralysis. However, both cases had no sufficient data to establish a direct link with vaccination<sup>29</sup>. Despite different neurological side effects related to all types of SARS-CoV-2 vaccines, no case of ME caused by HSV reactivation was reported. However, a few cases of Varicella Zoster Virus (VZV) reactivation were reported in the literature. According to the publication of Bostan et al<sup>30</sup>, a case of VZV reactivation in a 79-year-old patient was noted, 5 days after receiving an inactivated SARS-CoV-2 vaccine (COVAXIN). A more recent publication by Furer et al<sup>31</sup> reported the experience of six immunocompromised patients who developed the first episode of zoster closely after vaccination with the BNT162b2 mRNA vaccine (Pfizer). In a recent study published in July 2021 concerning cutaneous reactions reported after Pfizer or Moderna SARS-CoV-2 vaccination, only 10 out of 414 patients presented zoster<sup>32</sup>.

Our study seems to be the first case of a possible link between the first dose of a viral vector SARS-CoV-2 vaccine and herpetic meningoencephalitis. The exact mechanism remains elusive, but vaccine-induced immunomodulation may be involved. However, some limitations are present. First, we reported a single case. Moreover, a confident connection between the heterologous rAd26 and rAd5 vector-based SARS-CoV-2 vaccine (Sputnik®) and ME cannot be assured.

## CONCLUSIONS

SARS-CoV-2 vaccines have been proven to be effective and safe, but at the same time, it is crucial to keep in mind the potential neurological side effects of these vaccines.

Our case reported the first possible case of reactivation of herpetic meningoencephalitis after SARS-CoV-2 vaccine. This case highlights, not the perils of SARS-CoV-2 vaccination, but the complexity of the HSV-1-host interface. In conclusion, more epidemiological studies are needed to elucidate the possible link between vaccination and the reactivation of herpes virus infections.

## CONFLICT OF INTEREST:

The authors declare that they have no conflicts of interest.

## PATIENT'S CONSENT:

Obtained.

## REFERENCES

1. Tunkel AR, Glaser CA, Bloch KC, Sejvar JJ, Marra CM, Roos KL, Hartman BJ, Kaplan SL, Scheld WM, Whitley RJ; Infectious Diseases Society of America. The management of encephalitis: clinical practice guidelines by the Infectious Diseases Society of America. *Clin Infect Dis* 2008; 47: 303-327.

2. Kenfak A, Eperon G, Schibler M, Lamoth F, Vargas MI, Stahl JP. Diagnostic approach to encephalitis and meningoencephalitis in adult returning travellers. *Clin Microbiol Infect* 2019; 25: 415-421.
3. Piret J, Boivin G. Immunomodulatory Strategies in Herpes Simplex Virus Encephalitis. *Clin Microbiol Rev* 2020; 33: e00105-19.
4. Pebody RG, Andrews N, Brown D, Gopal R, De Melker H, François G, Gatcheva N, Hellenbrand W, Jokinen S, Klavs I, Kojouharova M, Kortbeek T, Kriz B, Prosenc K, Roubalova K, Teocharov P, Thierfelder W, Valle M, Van Damme P, Vranckx R. The seroepidemiology of herpes simplex virus type 1 and 2 in Europe. *Sex Transm Infect* 2004; 80: 185-191.
5. Hassman LM, Di Loreto DA Jr. Immunologic factors may play a role in herpes simplex virus 1 reactivation in the brain and retina after influenza vaccination. *IDCases* 2016; 6: 47-51.
6. Whitley RJ, Kimberlin DW, Roizman B. Herpes Simplex Viruses. *Clin Infect Dis* 1998; 26: 541-555. Scientific Research Publishing [Internet]. 2021 [cité 12 août 2021]. Disponible sur: [https://www.scirp.org/\(S\(lz5mqp453edsnp55rrgjt55\)\)/reference/referencespapers.aspx?referenceid=1729333](https://www.scirp.org/(S(lz5mqp453edsnp55rrgjt55))/reference/referencespapers.aspx?referenceid=1729333)
7. Kost RG, Straus SE. Postherpetic neuralgia--pathogenesis, treatment, and prevention. *N Engl J Med* 1996; 335: 32-42.
8. Utumi Y, Iseki E, Murayama N, Ichimiya Y, Arai H. [Limbic encephalitis caused by herpes simplex virus infection after vaccination against the influenza virus]. *Brain Nerve* 2010; 62: 615-619.
9. Les effets indésirables des vaccins contre la COVID-19 [Internet]. [cité 22 janv 2022]. Disponible sur: <https://www.who.int/fr/news-room/feature-stories/detail/side-effects-of-covid-19-vaccines>
10. Niebel D, Novak N, Wilhelmi J, Ziob J, Wilsmann-Theis D, Bieber T, Wenzel J, Braegelmann C. Cutaneous Adverse Reactions to COVID-19 Vaccines: Insights from an Immunodermatological Perspective. *Vaccines (Basel)* 2021; 9: 944.
11. The potential neurological effect of the COVID-19 vaccines: A review [Internet]. 2021 [cité 12 août 2021]. Disponible sur: <https://www.ncbi.nlm.nih.gov/pmc/articles/PMC8250748/>
12. Ophinni Y, Hasibuan AS, Widhani A, Maria S, Koesnoe S, Yuniastuti E, Karjadi TH, Rengganis I, Djauzi S. COVID-19 Vaccines: Current Status and Implication for Use in Indonesia. *Acta Med Indones* 2020; 52: 388-412.
13. Mikaeloff Y, Caridade G, Suissa S, Tardieu M. Hepatitis B vaccine and the risk of CNS inflammatory demyelination in childhood. *Neurology* 2009; 72: 873-880.
14. Haber P, DeStefano F, Angulo FJ, Iskander J, Shadomy SV, Weintraub E, Chen RT. Guillain-Barré syndrome following influenza vaccination. *JAMA* 2004; 292: 2478-2481.
15. Haber P, Sejvar J, Mikaeloff Y, De Stefano F. Vaccines and Guillain-Barré syndrome. *Drug Saf* 2009; 32: 309-323.
16. Rosenberg GA. Meningoencephalitis following an influenza vaccination. *N Engl J Med* 1970; 283: 1209.
17. Koubaa M, Mâaloul I, Lahiani D, Hammami B, Marrakchi C, Mnif Z. Réurrence de l'infection à herpès virus par la vaccination antigrippale A (H1N1). fait réel ou coïncidence ? *Rev Tunis D'Infectiologie* 2012; 6: 120-121.
18. Ehrengut W, Allerdist H. Uber neurologische Komplikationen nach der Influenza-schutzimpfung [Neurological complications after influenza vaccination (author's transl)]. *MMW Munch Med Wochenschr* 1977; 119: 705-710.
19. Drouet A, Guilloton L, Fresse S, Felten D. Méningite lymphocytaire après vaccination antigrippale [Meningoencephalitis following an influenza vaccination]. *Rev Med Interne* 2002; 23: 734.
20. González B, Fica A. Encefalitis recurrente post vacuna influenza anual [Recurrent encephalitis following annual influenza vaccine. Case report]. *Rev Chilena Infectol* 2016; 33: 226-228.
21. Goss AL, Samudralwar RD, Das RR, Nath A. ANA Investigates: Neurological Complications of COVID-19 Vaccines. *Ann Neurol* 2021; 89: 856-857.
22. Nakayama T. Causal relationship between immunological responses and adverse reactions following vaccination. *Vaccine* 2019; 37: 366-371.
23. Mailand MT, Frederiksen JL. Vaccines and multiple sclerosis: a systematic review. *J Neurol* 2017; 264: 1035-1050.
24. Tian M, Yang J, Li L, Li J, Lei W, Shu X. Vaccine-Associated Neurological Adverse Events: A Case Report and Literature Review. *Curr Pharm Des* 2020; 25: 4570-4578.
25. Polack FP, Thomas SJ, Kitchin N, Absalon J, Gurtman A, Lockhart S, Perez JL, Pérez Marc G, Moreira ED, Zerbini C, Bailey R, Swanson KA, Roychoudhury S, Koury K, Li P, Kalina WV, Cooper D, Frenck RW Jr, Hammitt LL, Türeci Ö, Nell H, Schaefer A, Ünal S, Tresnan DB, Mather S, Dormitzer PR, Şahin U, Jansen KU, Gruber WC; C4591001 Clinical Trial Group. Safety and Efficacy of the BNT162b2 mRNA Covid-19 Vaccine. *N Engl J Med* 2020; 383: 2603-2615.
26. Ura T, Okuda K, Shimada M. Developments in Viral Vector-Based Vaccines. *Vaccines (Basel)* 2014; 2: 624-641.
27. Voysey M, Clemens SAC, Madhi SA, Weckx LY, Folegatti PM, Aley PK, Angus B, Baillie VL, Barnabas SL, Borhat QE, Bibi S, Briner C, Cicconi P, Collins AM, Colin-Jones R, Cutland CL, Darton TC, Dheda K, Duncan CJA, Emary KRW, Ewer KJ, Fairlie L, Faust SN, Feng S, Ferreira DM, Finn A, Goodman AL, Green CM, Green CA, Heath PT, Hill C, Hill H, Hirsch I, Hodgson SHC, Izu A, Jackson S, Jenkin D, Joe CCD, Kerridge S, Koen A, Kwatra G, Lazarus R, Lawrie AM, Lelliott A, Libri V, Lillie PJ, Mallory R, Mendes AVA, Milan EP, Minassian AM, McGregor A, Morrison H, Mujadidi YF, Nana A, O'Reilly PJ, Padayachee SD, Pittella A, Plested E, Pollock KM, Ramasamy MN, Rhead S, Schwarzbald AV, Singh N, Smith A, Song R, Snape MD, Sprinz E, Sutherland RK, Tarrant R, Thomson EC, Török ME, Toshner M, Turner DPJ, Vekemans J, Villafana TL, Watson MEE, Williams CJ, Douglas AD, Hill AVS, Lambe T, Gilbert SC, Pollard AJ; Oxford COVID Vaccine Trial Group. Safety and efficacy of the ChAdOx1 nCoV-19 vaccine (AZD1222) against SARS-CoV-2: an interim analysis of four randomised controlled trials in Brazil, South Africa, and the UK. *Lancet* 2021; 397: 99-111. doi: 10.1016/S0140-6736(20)32661-1. Epub 2020 Dec 8. Erratum in: *Lancet*. 2021 Jan 9;397(10269):98.
28. Román GC, Gracia F, Torres A, Palacios A, Gracia K, Harris D. Acute Transverse Myelitis (ATM): Clinical Review of 43 Patients With COVID-19-Associated ATM and 3 Post-Vaccination ATM Serious Adverse Events With the ChAdOx1 nCoV-19 Vaccine (AZD1222). *Front Immunol* 2021; 12: 653786.
29. FDA Briefing Document. FDA Briefing Document Janssen Ad26.COV2.S Vaccine for the Prevention of COVID-19. 2021 févr p. 62.
30. Bostan E, Yalici-Armagan B. Herpes zoster following inactivated COVID-19 vaccine: A coexistence or coincidence? *J Cosmet Dermatol* 2021; 20: 1566-1567.
31. Furer V, Zisman D, Kibari A, Rimar D, Paran Y, Elkayam O. Herpes zoster following BNT162b2 mRNA COVID-19 vaccination in patients with autoimmune inflammatory rheumatic diseases: a case series. *Rheumatology (Oxford)* 2021; 60: SI90-SI95.
32. McMahon DE, Amerson E, Rosenbach M, Lipoff JB, Mustafafa D, Tyagi A, Desai SR, French LE, Lim HW, Thiers BH, Hruza GJ, Blumenthal KG, Fox LP, Freeman EE. Cutaneous reactions reported after Moderna and Pfizer COVID-19 vaccination: A registry-based study of 414 cases. *J Am Acad Dermatol* 2021; 85: 46-55.